




A rare and life-threatening condition: the role of radiologic imaging in conservatively treated duodenocaval fistula - case report.

Rola diagnostyki obrazowej w wykrywaniu przetoki pomiędzy dwunastnicą a żyłą główną dolną, leczonej zachowawczo - opis przypadku.

Marta Tatur¹ , Dominika Kostka², Maria Witkowska², Katarzyna Sklinda¹, Bartosz Mruk¹, Grażyna Rydzewska³, Jerzy Walecki¹

¹Zakład Diagnostyki Radiologicznej, Państwowy Instytut Medyczny MSWiA, Polska; ²Klinika Chorób Wewnętrznych, Nefrologii i Transplantologii, Państwowy Instytut Medyczny MSWiA w Warszawie, Polska; ³Klinika Chorób Wewnętrznych i Gastroenterologii, Państwowy Instytut Medyczny MSWiA w Warszawie, Polska

Abstract

A 56-year-old woman with cervical cancer treated previously with radio- and brachytherapy, and receiving palliative chemotherapy, with a right-sided nephrostomy, was admitted to the hospital with a suspected recurrence of a right kidney abscess. Diagnostic imaging has revealed a duodenocaval fistula (DCF) with an inflammatory reaction entraining the right ureter along with thrombosis of the inferior vena cava (IVC) and the left common iliac vein. Given the high perceived risk of surgical complications, the patient was treated conservatively and was discharged from the hospital in stable condition 5 weeks after admission.

Key words *cervical cancer, duodenocaval fistula, neoplastic infiltration*

Streszczenie

56-letnia kobieta z rakiem szyjki macicy leczona metodą radioterapii i brachyterapii oraz otrzymująca paliatywną chemioterapię, z prawostronną nefrostomią, została przyjęta do szpitala z podejrzeniem nawrotu ropnia prawej nerki. W badaniach obrazowych uwidoczono przetokę pomiędzy dwunastnicą, a żyłą główną dolną, z odczynem zapalnym obejmującym prawy moczowód oraz ze skrzepliną w żyłę główną dolną i lewej żyły biodrowej wspólnej. Ze względu na potencjalne duże ryzyko powikłań pooperacyjnych zdecydowano o leczeniu zachowawczym, pacjentka została wypisana ze szpitala w stanie stabilnym po 5 tygodniach od przyjęcia.

Słowa kluczowe *rak szyjki macicy, przetoka, infiltracja nowotworowa*

Autor korespondencyjny: Marta Tatur

Zakład Diagnostyki Radiologicznej, Państwowy Instytut Medyczny MSWiA, Polska
marta.sznurkowska@gmail.com

Otrzymano: 09.06.2023
Zaakceptowano: 23.08.2023
Opublikowano: 01.09.2023

Case report

Duodenocaval fistula (DCF) is a pathological connection between the inferior vena cava (IVC) and duodenum, that may exceptionally occur due to the proximity of these structures. The most common causes of DCF are migration of the caval filter, complications of right nephrectomy, radiotherapy, ingestion of a sharp object, penetrating abdominal injury, peptic ulcer disease and IVC graft erosion [1].

Patients with DCF usually present symptoms such as gastrointestinal bleeding and sepsis [1, 2]. Since these symptoms are nonspecific, the diagnosis is based on imaging studies, including studies of the upper gastrointestinal tract after administration of oral contrast, abdominal ultrasound, computed tomography (CT) scans, and magnetic resonance imaging (MRI).

In most of the cases reported in the literature, DCFs were surgically managed, with various results [1, 3]. The therapeutic decision depends on the patient's condition and should be implemented promptly, especially with signs of gastrointestinal bleeding. In stable patients with DCF, in whom the intervention could be associated with an increased risk of unsuccessful treatment and reduced quality of life, the risk-benefit ratio should be thoroughly assessed.

We present a case of a duodenocaval fistula treated non-operatively due to an increased risk of surgical complications in a patient who was previously treated with radiotherapy due to cervical cancer.

Case presentation

56-year-old female with a history of cervical cancer (diagnosed 4 years before hospitalization) treated with radio- and brachytherapy followed by palliative chemotherapy, and right-sided percutaneous nephrostomy inserted 8 weeks earlier was admitted to the Department of Internal Medicine and Nephrology due to suspected recurrence of right kidney abscess. The patient was hospitalized twice within 4 months before current admission and treated with IV antibiotics. On admission at the end of August 2022, the patient reported significant weakness, shivering, and weight loss. Her vital signs were as follows: temperature 36,7°C, heart rate 90/min., blood pressure 110/68 mmHg. Initial laboratory studies showed a hemoglobin 7.3 g/dL, hematocrit of 22,5%, WBC 18.64 10³/μL, CRP 111.8 mg/L procalcitonin 1.88 ng/ml, prolonged APTT 51,9 sec., elevated INR 1,36 and rest of blood chemistries were within normal range. Urinalysis demonstrated microhematuria, leukocyturia and moderate proteinuria. Blood cultu-

res were positive for high level aminoglycoside resistant (HLAR) *E. faecalis*, and urine culture was positive for ESBL producing *E. coli*.

Abdominal ultrasonography performed on the day of admission did not reveal any pathology, however due to increasing inflammatory parameters and a recent history of right kidney abscess it was decided to perform an abdominal computed tomography (CT).

Images were acquired after the intravenous injection of 80 mL of nonionic iodinated contrast material (Omnipaque).

The CECT (contrast-enhanced computed tomography) of the abdomen revealed a fistula between the third (horizontal) part of the duodenum and the IVC (Figure 1). The diameter of the fistula's lumen was approximately 15mm. An inflammatory reaction was seen in the surrounding tissues, engulfing the right ureter in a 2 cm section, adjacent to the aorta. Moreover, thrombosis of the IVC and the left common iliac vein was seen - a thrombus of about 87 mm in length with the front of the thrombus located 1.5 cm below the confluence of the renal veins. There were also gas bubbles within IVC thrombus. A right-sided nephrostomy tube was in adequate position, with no dilatation of the collecting system.

The complete parenteral nutrition was managed to the patient and she remained in stable condition. Moreover, proton pump inhibitor (PPI), and IV antibiotic therapy of vancomycin and meropenem were administered. 2 units of packed red blood cells (pRBCs) were transfused. Esophago-gastroduodenoscopy was performed on the 5th hospital day, which revealed a deep duodenal ulcer with a diameter of 2.5 cm.

It was suspected that complications after radiotherapy or a neoplastic infiltration were the possible cause of the fistula. However, after analyzing previous radiotherapy treatment it was determined that the duodenum was not included in the irradiation area, indicating that the most likely cause of fistula was progressive neoplastic infiltration.

Due to high perceived risk of surgical complications in the patient after radiation therapy conservative treatment was continued and repeated abdominal contrast-enhanced CT-scan on the 26th day of hospitalization demonstrated less gas within the thrombus located in the IVC and otherwise showed no significant differences from the previous study (Figure 2). Subsequently oral nutrition was gradually reintroduced. The patient was discharged 5 weeks after admission for further outpatient care and 6 months after discharge remained in a stable condition.

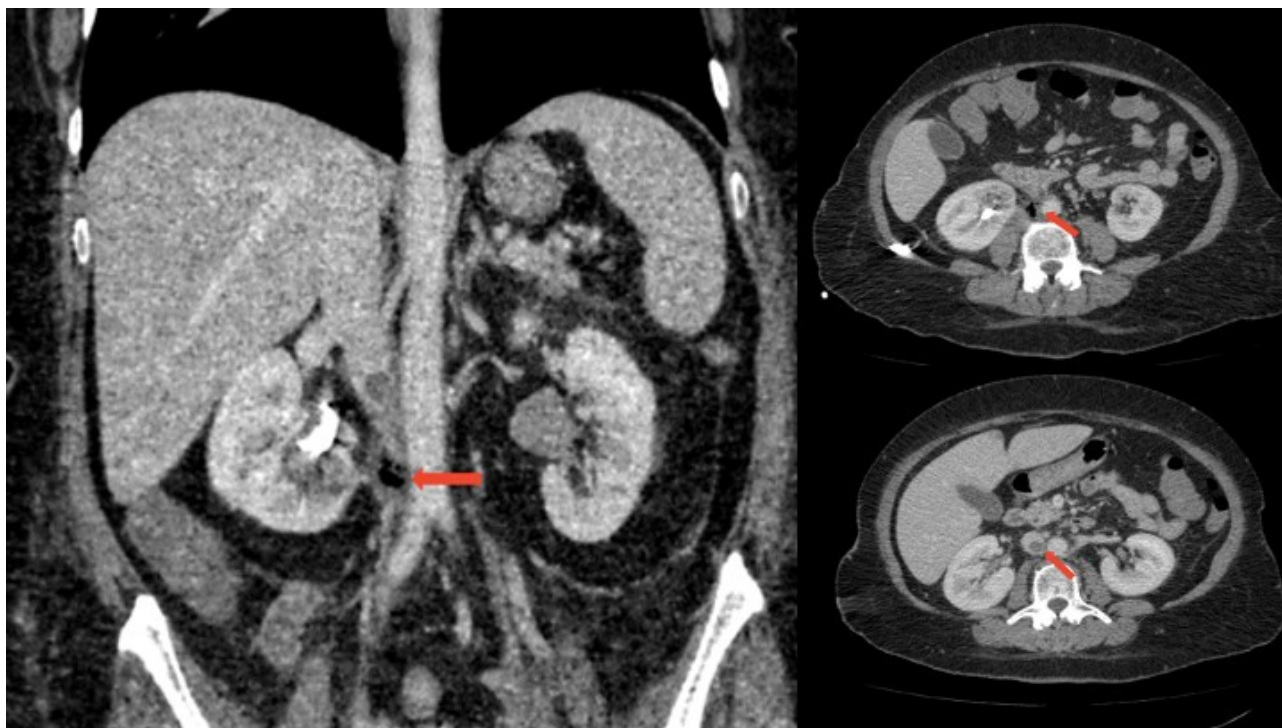

Figure 1 CECT of the abdomen show a fistula between horizontal part of duodenum and IVC. Thrombosis of the inferior vena cava (IVC) and a gas bubble in its lumen can also be observed.

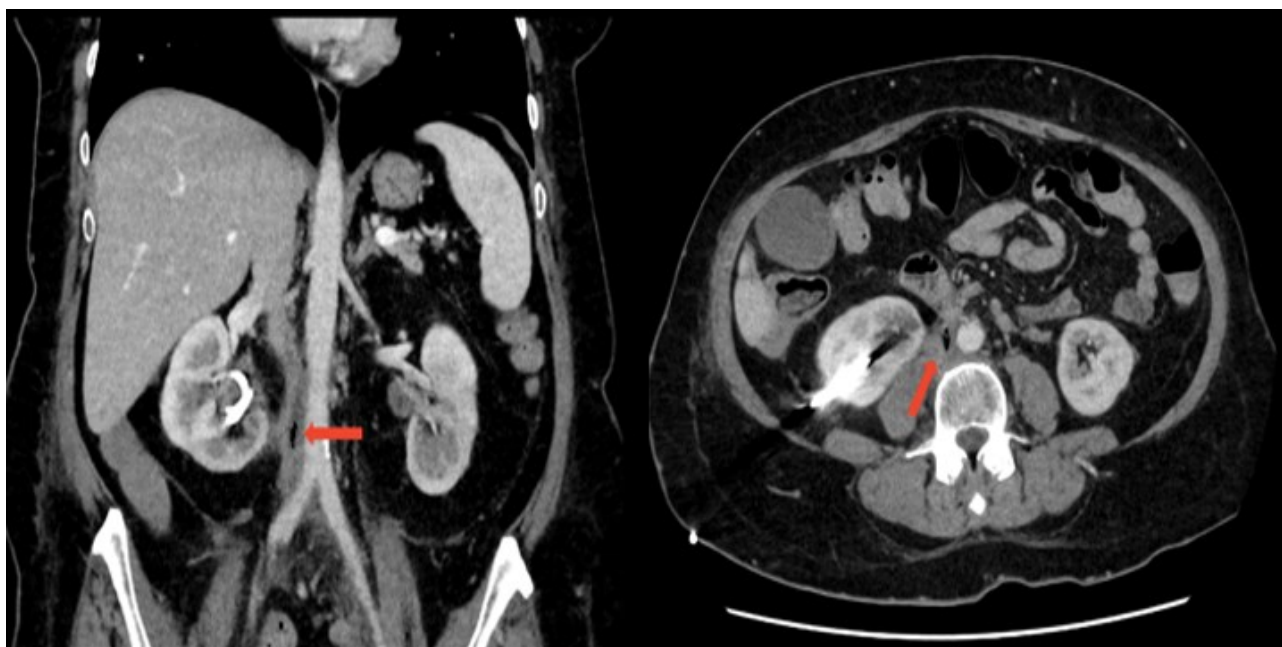


Figure 2 A follow-up CECT study 1 month after patient's admission to the hospital revealed less gas within the thrombus located in IVC. Otherwise the exam is unchanged.

Discussion

Duodenocaval fistulae are rare and difficult to diagnose but life-threatening condition, which may be induced by ingestion of foreign body, peptic ulcer disease, caval graft erosion or abdominal radiation therapy and cancer

progression [1, 2] as it was in our case. DCF has a high mortality rate (40%) [3] due to nonspecific symptoms which may impede establishing the correct diagnosis and decision making on appropriate treatment.

Imaging studies: CT or MRI, have a key role in the diagnosis and approach to DCF and provide us with measures to visualize IVC and the surrounding tissues [2, 4]. When DCF is suspected, abnormal gas collections or thrombus within the IVC should be sought, however, fluid collections around the duodenum and IVC may also indicate such a condition [2, 5]. It is essential to be aware that to visualize the thrombus within the IVC, it is necessary to perform the CT-study after administration of the contrast agent. It is worth emphasizing that CT and MRI are non-invasive studies which enable proper diagnosis of this pathology, and thus result in more rapid process of decision-making. If a suspicion of DCF is raised, structures around the duodenum and IVC should be viewed thoroughly and if the image is equivocal – repeating the examination after a few days should be considered [2].

Several case reports described patients who were usually treated surgically, which was also associated with significant mortality [1, 6]. Surgical intervention was predominantly based on suturing of the involved structures, sometimes with application of jejunal patch to prevent recurrence of the condition [1, 3, 6]. Reports of more extensive interventions can also be found such as pancreatoduodenectomy with excision of the IVC with graft interposition [1, 3].

To the best of the authors' knowledge, this is the second report in the literature of conservative treatment of the DCF [5], which reveals that surgical intervention is usually required.

Conclusion

Diagnostic imaging of the DCF, a condition of high risk of complications and postoperative mortality, should be preferably based on contrast-enhanced computed tomography or magnetic resonance imaging. Such methods enable physicians to make decisions on treatment measures, which can thereafter be adjusted to patient's individual risk-benefit ratio.

References

1. Guillem PG, Binot D, Dupuy-Cuny J et al. Duodenocaval fistula: a life-threatening condition of various origins. *J Vasc Surg* 2001;33(3):643-645. 10.1067/mva.2001.111741
2. Guo Y, Zhang YQ, Lin W. Radiological diagnosis of duodenocaval fistula: a case report and literature review. *World J Gastroenterol* 2010;16(18):2314-2316. 10.3748/wjg.v16.i18.2314
3. Perera GB, Wilson SE, Barie PS et al. Duodenocaval fistula: a late complication of retroperitoneal irradiation and vena cava replacement. *Ann Vasc Surg* 2004;18(1):52-58. 10.1007/s10016-003-0097-8
4. Moran EA, Porterfield JR, Nagorney DM. Duodenocaval fistula after irradiation and resection of a retroperitoneal sarcoma. *J Gastrointest Surg* 2008;12(4):776-778. 10.1007/s11605-007-0256-2
5. Ippolito D, Querques G, Drago SG et al. Duodenocaval Fistula in a Patient with Inferior Vena Cava Leiomyosarcoma Treated by Surgical Resection and Caval Polytetrafluoroethylene Prosthesis. *Case Rep Radiol* 2015;2015575961. 10.1155/2015/575961
6. Türkoğlu MA, Vural V, Turan Mİ et al. Surgical approach for duodenocaval fistula secondary to inferior vena caval graft penetration. *Ankara Üniversitesi Tıp Fakültesi Mecmuası* 2015;68(3):143-145. DOI: 10.1501/Tıpfak_0000000906